

Case report

A case of aortopulmonary window mimicking common arterial trunk on fetal echocardiography



Marcin Wiecheć^{1,2,3} , Agnieszka Nocuń² , Malwina Merta³ ,
Katarzyna Januszewska⁴ , Edward Malec⁴ 

¹Department of Gynaecology and Obstetrics, Jagiellonian University Medical College, Krakow, Poland

²Centre of Ultrasound Diagnostics MWU DobreUSG, Krakow, Poland

³Obstetrics and Perinatology Clinic, University Hospital in Krakow, Poland

⁴Cardiosurgery Clinic, Polish Mother's Health Centre Institute, Lodz, Poland

Abstract

Aortopulmonary window (APW) is a rare congenital cardiac anomaly characterised by abnormal communication between the aorta and the pulmonary trunk in the presence of separately formed semilunar valves. We present a case that was initially diagnosed in prenatal life at 21 weeks as common arterial trunk. Follow-up scans starting from 31 weeks revealed APW type I in the setting of tetralogy of Fallot (S, D, S) with a right-sided aortic arch with wide interatrial communication. The neonate was born at 38 weeks of gestation by caesarean section; its birth weight was 2825 g. The postnatal echocardiogram confirmed the prenatal diagnosis provided later in gestation. Three weeks after birth, the child was scheduled for surgery: complete repair and APW closure using an autologous pericardial patch, excision of trabeculae in the right ventricular outflow tract (RVOT), transannular reconstruction below the RVOT, reconstruction of the RVOT, and partial ASD closure. The child was discharged from the hospital, weighing 3300 g, with 97% saturation. APW may remain undiagnosed until adulthood. A late diagnosis may result in congestive heart failure and irreversible damage to the pulmonary vessels. Early detection of APW, preferably in the prenatal period, remains the key issue in terms of this condition.

Key words: fetal echocardiography, tetralogy of Fallot, aortopulmonary window.

Corresponding author:

Agnieszka Nocuń MD, PhD
Centre of Ultrasound Diagnostics MWU DobreUSG
Gen. Fieldorfa-Nila 14 /JU3
31-209 Krakow, Poland
e-mail: a.nocun@gmail.com

Introduction

Aortopulmonary window (APW) is a rare congenital cardiac anomaly characterised by abnormal communication between the aorta and the pulmonary trunk in the presence of separately formed semilunar valves. It accounts for approximately 0.1% of all types of congenital heart disease (CHD) and may occur as an isolated anomaly or, more often, concomitantly with other abnormalities such as atrial septal defect,

ventricular septal defect, tetralogy of Fallot, and aortic arch anomalies [1-7].

Most patients demonstrate left-to-right shunt; it is also essential to determine the exact location and size of the communication between the main arteries. Most anomaly cases are diagnosed during infancy; however, a prenatal diagnosis was reported and when possible, it constitutes an important role for treatment planning and thus prevention of cardiac failure development [8].

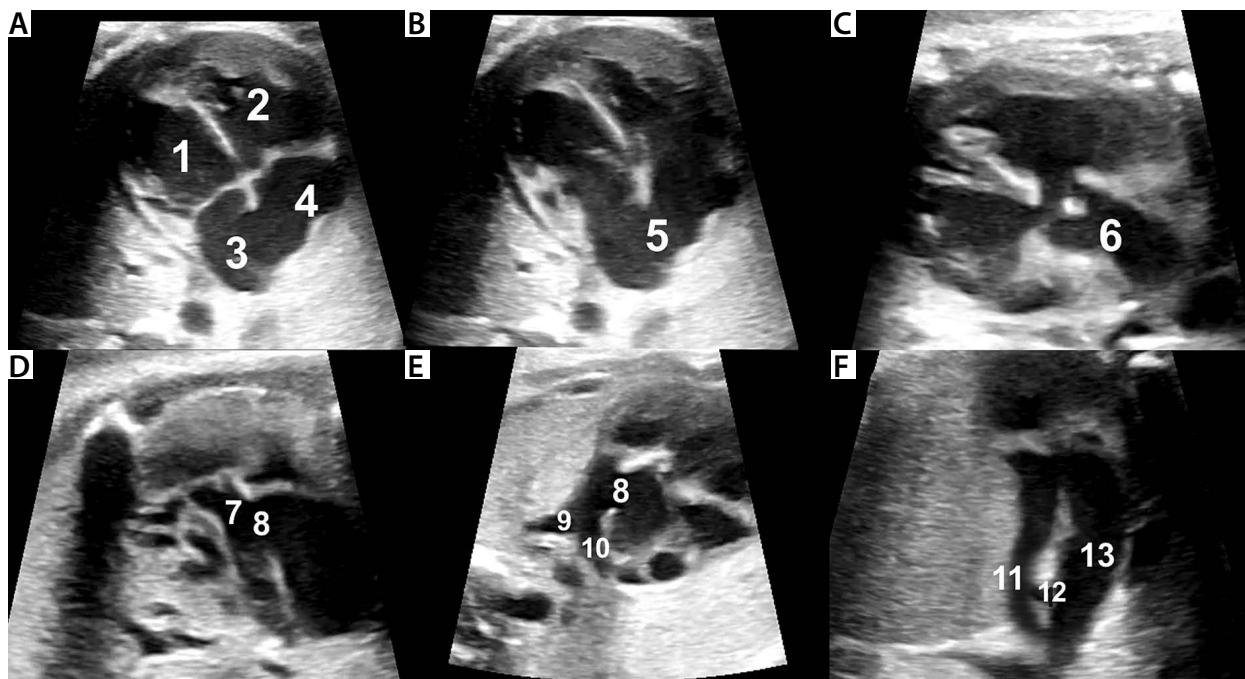


Figure 1. Fetal echocardiography at 31 weeks of gestation: A – a four-chamber view in systole; B – a four-chamber view in diastole; C – the left ventricular outflow tract; D – the right ventricular outflow tract; E – a short-axis oblique view showing aortopulmonary window; F – a three-vessel and tracheal view – the right-sided aortic arch and the left-sided arterial duct are visualised

1 – left ventricle, 2 – right ventricle, 3 – left atrium, 4 – right atrium, 5 – interatrial communication, 6 – aorta, 7 – pulmonary trunk, 8 – aortopulmonary window, 9 and 10 – left and right pulmonary arteries, 11 – ductus arteriosus, 12 – trachea, 13 – aorta.

Case report

A 31-year-old pregnant patient (multiparous) was referred to the tertiary centre in Krakow, Poland for a third opinion consultation due to a diagnosed fetal cardiac anomaly and for further postnatal management planning. No complications were observed during pregnancy. The first scan at another reference centre performed at 21 weeks of gestation revealed the common arterial trunk (CAT), suspected right atrial isomerism, an additional left toe, and a two-vessel umbilical cord. The amniotic fluid aCGH test did not detect any fetal genomic imbalance. The next fetal echocardiogram was performed at 23 weeks of gestation in another tertiary institution and revealed CAT type A1. In addition to the ventricular septal defect, the common arterial trunk was described and characterised by a short pulmonary trunk divided into 2 pulmonary branches. The patient decided to request a third opinion at 31 weeks of gestation. Two arterial valves and signs of tetralogy of Fallot (S, D, S) with a right-sided aortic arch and aortopulmonary window type I with wide interatrial communication were observed on this scan (Figures 1 and 2). The diameter of aortopulmonary window was 6.1 mm.

Considering the new findings, the patient received an adequate consultation from the team of perinatologists and cardiologists. The neonate was born at 38 weeks of gestation by caesarean section due to 2 prior caesarean procedures and premature rupture of membranes; its birth weight was 2825 g. The Apgar score after delivery was 7/9/9. As the newborn demonstrated clinical signs of tachypnoea and irregular breaths with intercostal retractions, CPAP non-invasive ventilation was

initiated and continued for several hours. In addition to prenatally detected abnormalities, a left pelvic kidney was identified. Further bronchoscopy revealed laryngomalacia, mild retrognathism, and laryngeal hypoplasia. An X-ray exam was performed after birth and showed the cardiac silhouette shifted to the left as well as signs of increased pulmonary flow. The post-natal echocardiogram confirmed the prenatal diagnosis provided by the third opinion: situs solitus; atrio-ventricular (AV) and ventriculo-arterial (VA) alignments; a normal pulmonary venous connection; normal function of atrioventricular valves with a normal inflow pattern; a large atrial septal defect (ASD) of 8 mm with left-to-right shunt; a ventricular septal defect (VSD) of 9 mm with left-to-right shunting with the 16 mmHg gradient; a dextral position of the aorta; left ventricular outflow tract (LVOT) without stenosis; a slightly dysplastic, probably two-cuspid aortic valve with regurgitation grade I/II; an aortic valve (AV) ring 9.1 mm (Z-score 1.84); a right-sided aortic arch; a pulmonary valve ring 5.2 mm (Z-score -3.2) with a minor flow turbulence 1.9 m/s; and an aortopulmonary window of 11 mm (Figure 3).

In functional assessment the shortening fraction (FS) was 30.7%, and the ejection fraction (EF) measured 62.2%. During the preoperative period, enteral feeding was initiated due to poor weight gain. Moreover, signs of cardiovascular failure (tachypnoea, tachycardia) were observed, and treatment was administered (captopril, propranolol, diuretics). Three weeks after birth, the child was scheduled for surgery: complete repair and APW closure using an autologous pericardial patch, excision of trabeculae in the right ventricular outflow tract

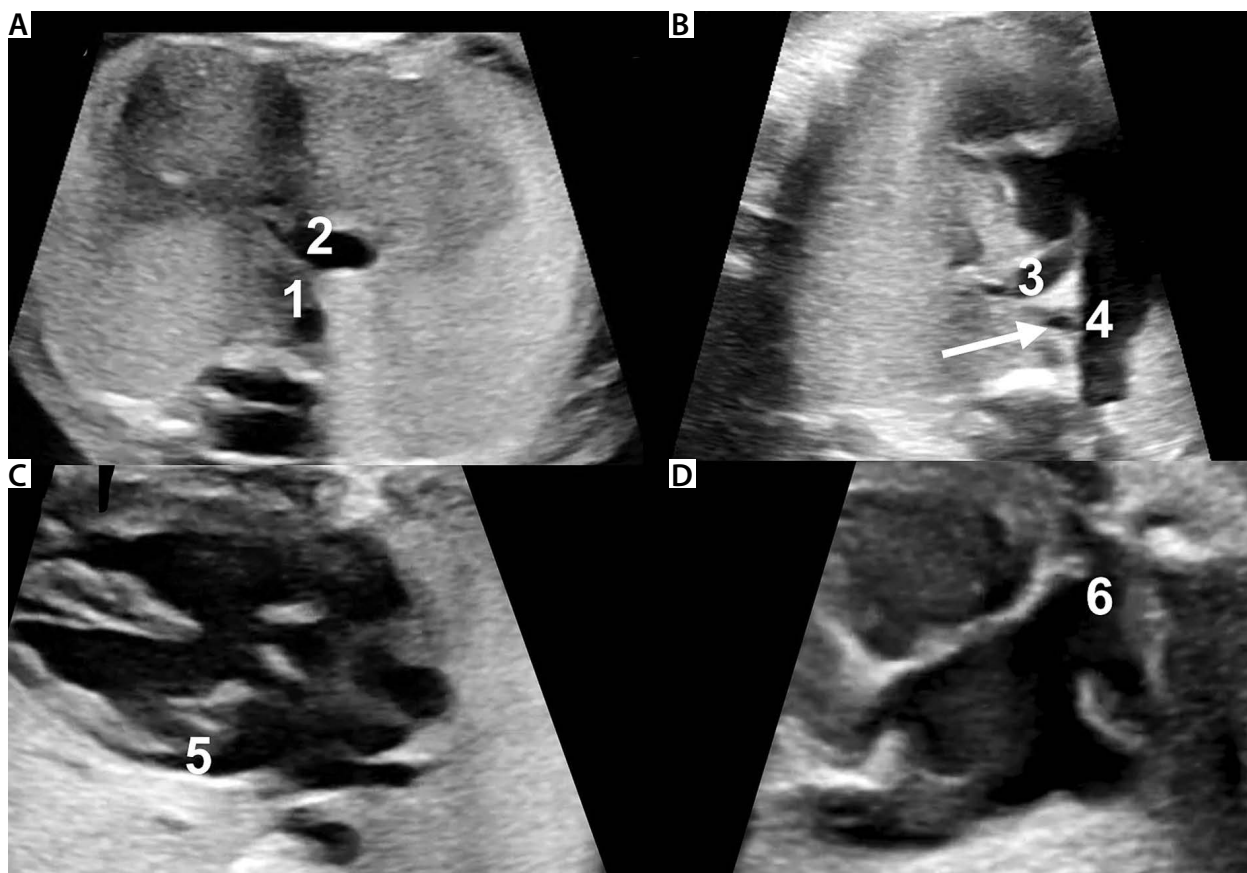


Figure 2. Fetal echocardiography at 31 weeks of gestation: A – an upper abdominal view: ipsilateral location of the descending aorta and the inferior vena cava; B – the right ventricular outflow tract: aortopulmonary window and the right-sided aortic arch are visualised; C – a five-chamber view: the left atrial appendage is seen; D – a venous systemic return view: the right atrial appendage is observed

1 – descending aorta, 2 – inferior vena cava, 3 – pulmonary trunk, 4 – aorta, 5 – left atrial appendage, 6 – right atrial appendage, arrow – trachea.

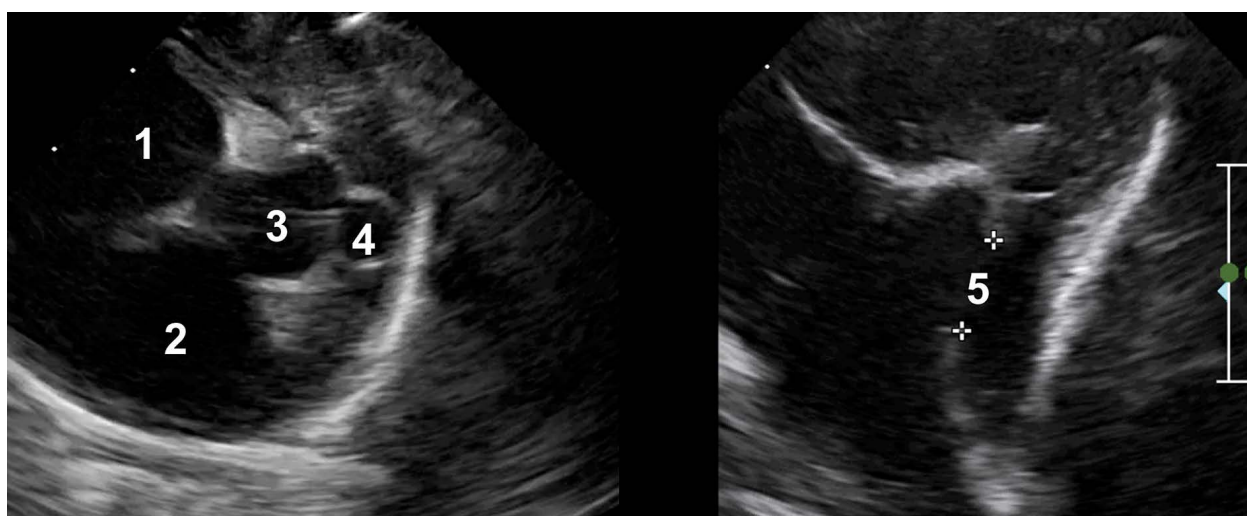

Figure 3. Postnatal echocardiography: the left image – a short axis view (vascular) with a confirmed presence of 2 annuli of the semilunar valves. Right image: the right ventricular outflow tract

1 – left atrium, 2 – right atrium, 3 – aorta, 4 – pulmonary trunk, 5 – aortopulmonary window.

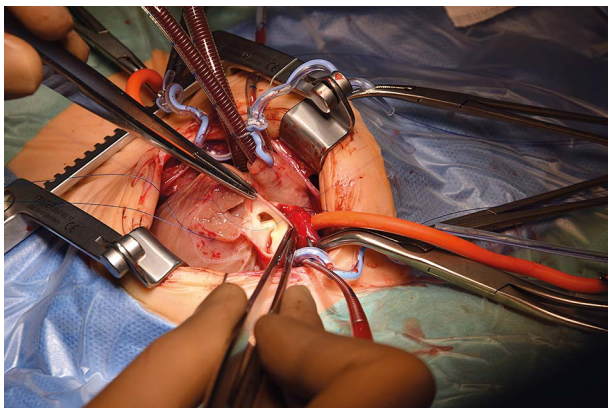


Figure 4. An intraoperative image of the aortopulmonary window closure procedure

(RVOT), transannular reconstruction below the RVOT, reconstruction of the RVOT using autologous pericardial patch, and partial ASD closure (Figure 4).

Intraoperatively, the left coronary artery was found to originate high just below the lower edge of the window. The postoperative condition of the child was good. The patient was intubated and mechanically ventilated for 72 hours and stayed in the Intensive Care Unit for 6 days; the postoperative course was uneventful. The pre-discharge echocardiogram findings were as follows: good systolic function of both ventricles, right ventricular hypertrophy, bidirectional shunt through a minor ASD (left intentionally), no residual shunt regarding the ventricles, laminar flow through the atrioventricular valves with no significant regurgitation, laminar flow through the RVOT, minor flow turbulence at the origin of the pulmonary arteries from the pulmonary trunk, significant pulmonary valve regurgitation following transannular correction, laminar flow through the LVOT and AV maximum velocity of 1 m/s; mild aortic regurgitation, slightly dilated ascending aorta 14-15 mm (Z-score +4,5); no flow abnormalities; and absence of shunts. The child was discharged from the hospital weighing 3300 g with 97% saturation.

Discussion

Only isolated cases of APW in association with TOF have been described in the literature [8-14]. Just 40 cases of APW have been detected prenatally, and among them, the combination with TOF was described in only 2 articles (Table 1) [15-34].

Differential diagnosis

The vast majority of APW cases are associated with coarctation of the aorta, hypoplasia of the aortic arch, and sometimes its interruption. The reason for this combination is a significant left-right leak between the great vessels. These cases can be detected at the height of the three-vessel and trachea view. Subsequently, when searching for potential locations of the left-right leak after excluding subaortic VSD, the examiner may encoun-

ter APW. In our case, the situation was different. We detected anterior malalignment VSD with aortic dextroposition and hypoplasia of the conus arteriosus with secondary pulmonary stenosis, typical features of TOF. However, additional APW caught our attention. Of course, in cases of earlier pregnancy or more pronounced hypoplasia of the conus arteriosus, such an image may resemble CAT. However, the presence of ductus arteriosus in this situation in the absence of the aortic arch interruption should allow the exclusion of CAT. First of all, the common arterial trunk characterised by the presence of only one semi-lunar valve should be distinguished from APW because both aortic and pulmonary valves were observed here. The initial diagnosis of the presented case, made during the first and second evaluations, is associated with different management approaches regarding treatment and further prognosis. Moreover, the right-sided aortic arch that results in the shift of the descending aorta to the ipsilateral position with inferior caval vein may cause additional diagnostic difficulties because it may be misinterpreted as a sign of right atrial isomerism. In this case, a precise assessment of morphology of the atria, liver, spleen, and the other abdominal organs was performed, which is particularly important because the right-sided aortic arch and the common arterial trunk are observed in 32% and 10% of cases of right atrial isomerism, respectively [35].

Prognosis

A physical neonatal exam in cases like the one presented in our article frequently reveals systolic or continuous heart murmur, tachypnoea, and signs of cardiac failure. In addition, in the case of decreased coronary perfusion pressure, so-called coronary steal syndrome, may develop, which is more common, when accompanied by tachycardia. Larger shunts lead to pulmonary hypertension. Therefore, it is important to repair the defect during the first months of life so that irreversible damage of the pulmonary vessels can be avoided. It should be remembered that in the case of a combination of significant valvular or infundibular pulmonary stenosis with APW, the leak through the window significantly supports the pulmonary circulation, eliminating the effect of reducing the flow through the pulmonary valve from the right ventricle [36]. For patients with diagnosed APW, surgical closure of the defect or transcatheter placement of an implant is recommended [3, 7, 37].

Conclusions

Aortopulmonary window may remain undiagnosed until adulthood. A late diagnosis may result in congestive heart failure and irreversible damage to the pulmonary vessels. This is why early detection of APW, preferably in the prenatal period, remains the key issue in terms of this condition [33, 38].

Conflict of interest

The authors declare no conflict of interest.

Table 1. Reported diagnosis of aortopulmonary window in the antepartum period [15–34]

Author (year), country	Gestational age at the time of diagnosis	APW (type according to Richardson)	Other cardiac abnormalities	Extra cardiac abnormalities	Obstetric outcome	Genetic tests	Surgical treatment	Outcome
Our case Krakow, Poland	31 weeks	APW type I	Tetralogy of Fallot, right aortic arch, ASD	None	CS at 38 weeks	Normal CGH array	3 rd week	Alive
Sylwestrzak et al. (2021), Łódź, Poland,	34 weeks	APW type I	Atrial septal defect	None	CS at 38 weeks	NA	At 12 th day of life	Alive
Żidere et al. (2020), London, UK	32 weeks	APW type I	Ventricular septal defect, right aortic arch	None	At term	Normal CGH array	3 rd week	Alive
Quintero et al. (2019), London, UK	Mid trimester	APW type I	Double aortic arch	None	VD at 38 weeks, weight	NK, 22q11 deletion excluded	At 12 th day of life.	Alive
Kaya et al. (2019), Istanbul, Turkey	24 weeks	APW type I	Not found	None	CS at 27 weeks (because of HELLP syndrome)	NK, 22q11 deletion excluded	Not performed	Died at the age of 11 days
	25 weeks, (monochorionic diamniotic pregnancy)	APW type I	Hypoplastic left heart	None	CS at 28 weeks due to preterm labour	NA	Not performed	Died at the age of 9 days
Li et al. (2018), Beijing, China	27 weeks	APW type II	IAA type A, aortic origin of the right PA	None	VD at term	NK 22q11 not studied	Not performed	Died after 9 weeks
	27 weeks	APW type II	VSD	None	CS at 39 weeks	NK, 22q11 not studied	Surgical repair	Alive
	25 weeks	APW type III	Right aortic arch	None	CS at 37 weeks	NK, 22q11 not studied	Surgical repair	Alive
	27 weeks	APW type III	Not found	None	VD at term	NK, 22q11 not studied	Surgical repair	Alive
	26 weeks	APW type II	IAA type A, aortic origin of right PA	None	TOP at 26 weeks	NK, 22q11 not studied	–	–
	25 weeks	APW type III	Not found	None	VD at term	NK, 22q11 not studied	Surgical repair	Alive
	29 weeks	APW type II	Right aortic arch	None	VD at term	NK, 22q11 not studied	Surgical repair	Alive
	30 weeks	APW type II	Not found	None	VD at term	NK, 22q11 not studied	Surgical repair	Alive
Yu et al. (2018), Beijing, China	24 weeks	APW type II	VSD, CoA	NA	TOP	NK, 22q11 deletion excluded	–	–
	24 weeks	APW type I	Absent arterial duct	NA	TOP	NK, 22q11 deletion excluded	–	–
	23 weeks	APW type II	Interrupted aortic arch, aortic origin of right PA	NA	TOP	NK, 22q11 deletion excluded	–	–
	21 weeks	APW type II	Absent arterial duct	NA	TOP	Not studied	–	–
	23 weeks	APW type II	Aortic origin of right PA	NA	TOP	NK, 22q11 deletion excluded	–	–
	28 weeks	APW type II	DORV, absent arterial duct, VSD	NA	TOP	NA	–	–
Vaidyanathan et al. (2018), Kochi, Kerala, India	34 weeks	APW type II	IAA type A	NA	VD at 37 weeks	NA	On 4 th day	Alive

Table 1. Cont.

Author (year), country	Gestational age at the time of diagnosis	APW (type according to Richardson)	Other cardiac abnormalities	Extracardiac abnormalities	Obstetric outcome	Genetic tests	Surgical treatment	Outcome
Zhang et al. (2018), Beijing, China	24 weeks	APW type II	Berry syndrome: AORPA, intact ventricular septum, CoA	NA	TOP	11q14.2 gene deletion	–	–
	27 weeks	APW type II	Berry syndrome: AORPA, intact ventricular septum, IAA type A	NA	TOP	NA	–	–
	29 weeks	APW type II	Berry syndrome: AORPA, intact ventricular septum, IAA type A	NA	TOP	NA	–	–
	23 weeks	APW type II	Berry syndrome: AORPA, intact ventricular septum, IAA type A	NA	Lost follow-up	–	–	–
Tongprasert et al. (2017), Chiang Mai, Thailand	19 weeks	APW type I	Not found	hydrocephalus	TOP	NK, 22q11 not studied	–	–
	20 weeks	APW type I	Abnormal course of PA	None	VD at 27 weeks, 1100 g	NK, 22q11 not studied	Not performed	Died on 7 th day
	21 week	APW type II	Abnormal course of great arteries	None	VD at term, 2900g	NK, 22q11 deletion excluded	Waiting for surgery	Alive
Louis-Jacques et al. (2017), USA	30 weeks	APW type III	Not found	Multiple fetal anomalies, Dandy-Walker malformation	CS at 38 weeks	NK, terminal gain in 7p and loss in 6p	Not performed	Death on 4 th day
	34 weeks	APW type I	Not found	None	VD at term	NK, 22q11 deletion excluded	On day 36	Alive
Fotaki et al. (2017), London, UK	20 weeks	APW type I	IAA, ectopic position of right kidney	None	VD at term	NK, 22q11 deletion excluded	On 7 th day	Alive
	22 weeks (IVF, DC/DA twins)	APW type I	IAA type A	None	CS at 37 weeks	NK, 22q11 deletion excluded	At 5 th day	Alive
Więckowska et al. (2015), Lodz, Poland	26 weeks	small APW type I	PVS	None	CS at 39 weeks	NA	Not performed	Alive
	NA	APW type II	DORV, VSD, D-malposition of the great arteries	None	CS at 38 weeks	Duplication of DNA from 5p12 and deletion from 16p12.2	At 5 th day	Reoperation at 6 months. Survived
Kadohira et al. (2012), Shinjuku-ku, Japan	29 weeks	APW type I	IAA type B	None	CS at 38 weeks	NA	At 5 th day	Alive
Corbacioglu et al. (2012), Istanbul, Turkey	24 weeks (MC/MA twins)	APW type I	IAA type B	None	CS at 35 weeks	NK, 22q11 deletion excluded	At 10 th day	Complicated postoperative course, reoperation, died

Table 1. Cont.

Author (year), country	Gestational age at the time of diagnosis	APW (type according to Richardson)	Other cardiac abnormalities	Extra cardiac abnormalities	Obstetric outcome	Genetic tests	Surgical treatment	Outcome
Aslan et al. (2011), Istanbul, Turkey	33 weeks	APW type I	Not found	None	CS at 37 weeks	NA	At 1 week	Complicated postoperative course, died
Alvarez et al. (2011), Sevilla, Spain	26 weeks	APW type III	ASD	None	VD at term	NK, 22q11 deletion excluded	At 4 weeks	Alive
Hayashi et al. (2010), Osaka, Japan	29 weeks	APW type I	IAA type A	None	Delivered at term	NK, 22q11 deletion not studied	At 5 th day	Alive
Patel et al. (2007), USA	30 weeks	APW type I	Tetralogy of Fallot	None	Delivered at term	NK, 22q11 deletion excluded	A few days after birth	Died postoperatively
Valsangiacomo et al. (2002), Canada	32 weeks	APW type I	Right aortic arch	None	Delivered at term	NA	NA	NA
Collinet et al. (2002), Lille, France	23 weeks	APW type I	VSD, ASD	None	Delivered at term	NA	At 3 weeks	Alive
Total					Total 42 (1 lost to follow-up, 11 TOP, 30 deliveries)			21 survivors (8 deaths, 2 lost to follow-up)

AOBPA – aortic origin of right pulmonary artery, APW – aortopulmonary window, ASD – atrial septal defect, CoA – coarctation of aorta, CS – caesarean section, DC/DA – dichotomous/diamniotic, DORV – double outlet right ventricle, IAA – interrupted aortic arch, NA – not available, NK – normal karyotype, PA – pulmonary artery, PVS – pulmonary valve stenosis, TOP – termination of pregnancy, VD – vaginal delivery, VSD – ventricular septal defect.

REFERENCES

- Collinet P, Chatelet-Cheront C, Houze de l'Aulnoit D, Rey C. Prenatal diagnosis of an aortopulmonary window by fetal echocardiography. *Fetal Diagn Ther* 2002; 17: 302-307.
- Backer CL. Aortopulmonary window and aortic origin of a pulmonary artery. In: *Pediatric Cardiac Surgery*. Mosby, Philadelphia 2003.
- Elliotson J. Case of malformation of the pulmonary artery and aorta. *Lancet* 1830; 1: 247-251.
- Mori K, Ando M, Takao A, Ishikawa S, Imai Y. Distal type of aortopulmonary window. *Br Heart J* 1978; 40: 681-689.
- Mavroudis C. Congenital heart surgery nomenclature and database project: aortopulmonary window. *Ann Thorac Surg* 2000; 69: S44e9.
- Backer CL, Mavroudis C. Surgical management of aortopulmonary window: a 40-year experience. *Eur J Cardiothorac Surg* 2002; 21: 773-779.
- Di Bella I, Gladstone DJ. Surgical management of aortopulmonary window. *Ann Thorac Surg* 1998; 65: 768-770.
- Kuehn A, Oberhoffer R, Vogt M, Lange R, Hess J. Aortopulmonary window with ventricular septal defect and pulmonary atresia: prenatal diagnosis and successful early surgical correction. *Ultrasound Obstet Gynecol* 2004; 24: 793-796.
- Patel C, Smith G, Lane J. Tetralogy of Fallot with an aortopulmonary septal defect. *J Ultrasound Med* 2007; 26: 1115-1117.
- Koestenberger M, Nagel B, Cvirn G, Beitzke A. Aortopulmonary window, critical pulmonary stenosis, and hypoplastic right ventricle. *Clin Res Cardiol* 2008; 97: 467-469.
- Carminati M, Borghi A, Valsecchi O, et al. Aortopulmonary window co-existing with tetralogy of Fallot: echocardiographic diagnosis. *Pediatr Cardiol* 1990; 11: 41-43.
- Castaneda AR, Kirklin JW. Tetralogy of Fallot with aorticopulmonary window. Report of two surgical cases. *J Thorac Cardiovasc Surg* 1977; 74: 467-468.
- Craford FA Jr, Watson DG, Joransen JA. Tetralogy of Fallot with coexisting type II aortopulmonary window. *Ann Thorac Surg* 1981; 31: 178-181.
- McElhinney DB, Reddy VM, Tworetzky W, Silverman NH, Hanley F. Early and late results after repair of aortopulmonary septal defects and associated anomalies in infants < 6 months of age. *Am J Cardiol* 1998; 81: 195-201.
- Fotaki A, Novaes J, Jicinska H, Carvalho JS. Fetal aortopulmonary window: case series and review of the literature. *Ultrasound Obstet Gynecol* 2017; 49: 533-539.
- Malakan Rad E, Sheykhan T, Zeinaloo AA. Atrial and ventricular ejection force of the fetal heart: which of the four chambers is the dominant? *Ann Pediatr Cardiol* 2019; 12: 220-222.
- Giorgione V, Parazzini F, Fesslova V, Cipriani S, Candiani M, Inversetti A, et al. Congenital heart defects in IVF/ICSI pregnancy: systematic review and meta-analysis. *Ultrasound Obstet Gynecol* 2018; 51: 33-42.
- Zidere V, Vigneswaran T, Lloyd DF, To M, Pushparajah K, Austin C. Aortopulmonary window and right aortic arch in a fetus. *Prenat Cardio* 2020; 10: 62-64.
- Bernal Quintero D, Manning N, Wolfenden J, Hughes ML, Marek J. Prenatal diagnosis of double aortic arch in association with an aortopulmonary window. *Eur Heart J Cardiovasc Imaging* 2019; 20: 1180.
- Li W, Bin G, Jiang W, Shuang Y. Prenatal diagnosis of aortopulmonary window by 2-dimensional echocardiography: summary of 8 cases. *J Ultrasound Med* 2019; 38: 795-803.
- Yu S, Han J, Gao S, Liu X, Gu X, Zhang Y, et al. The prenatal diagnosis of aortopulmonary window by fetal echocardiography. *Echocardiography* 2018; 35: 1835-1840.
- Vaidyanathan B, Vijayaraghavan A, Karmagaraj B, Kottayil B. Prenatal diagnosis of distal aortopulmonary window with type A aortic arch interruption with 4-dimensional spatiotemporal image correlation rendering. *Circ Cardiovasc Imaging* 2018; 11: e007721.

23. Zhang X, Liu X-W, Gu X-Y, Han J-C, Hao X-Y, Fu Y-W, et al. Prenatal diagnosis of Berry syndrome by fetal echocardiography: a report of four cases. *Echocardiography* 2018; 35: 563-565.
24. Tongprasert F, Sittiwangkul R, Jatavan P, Tongsong T. Prenatal diagnosis of aortopulmonary window: a case series and literature review. *J Ultrasound Med* 2017; 36: 1733-1738.
25. Louis-Jacques AF, Običan SG, Nguyen T, Odibo A. Prenatal diagnosis of aortopulmonary window associated with aberrant subclavian artery. *Cardiol Young* 2017; 27: 1441-1443.
26. García C, Álvarez T, Bravo C, Pérez-Caballero R, Viadero MT, Gámez E, et al. Prenatal diagnosis of an aortopulmonary window with an interrupted aortic arch. *J Ultrasound Med* 2016; 35: 2087-2093.
27. Tunks RD, Steed RD, Lodge AJ. Surgical approach to a rare case of double-outlet right ventricle and aortopulmonary window. *Cardiol Young* 2016; 26: 172-174.
28. Kadohira I, Miyakoshi K, Yoshimura Y. Prenatal images of the aortopulmonary window with an interrupted aortic arch. *Pediatr Cardio* 2013; 34: 1288-1289.
29. Corbacioglu Esmer A, Gul A, Dagdeviren H, Turan Bakirci I. Aortopulmonary septal defect with interrupted aortic arch in a monochorionic diamniotic twin pregnancy. *J Med Ultrason* 2012; 39: 275-278.
30. Alvarez R, García-Díaz L, Coserria F, Hosseinpour R, Antiñolo G. Aortopulmonary window with atrial septal defect: prenatal diagnosis, management and outcome. *Fetal Diagn Ther* 2011; 30: 306-308.
31. Hayashi G, Inamura N, Kayatani F, Kawazu Y, Hamamichi Y. Prenatal diagnosis of aortopulmonary window with interrupted aortic arch by fetal echocardiography. *Fetal Diagn Ther* 2009; 27: 97-100.
32. Valsangiacomo ER, Smallhorn JE. Prenatal diagnosis of aortopulmonary window by fetal echocardiography. *Circulation* 2002; 105: e192-e192.
33. Więckowska K, Węgrzynowski J, Zych-Krekora K, Kwiatkowska J, Słodki M, Respondek-Liberska M. Antenatal echocardiographic diagnosis of an aortopulmonary window combined with pulmonary stenosis in neonate. A case report. *Prenat Cardio* 2015; 5: 33-37.
34. Sylwestrzak O, Dulko J, Krekora M, Gulczyńska E, Kopala M, Respondek-Liberska M. Prenatal diagnosis of aortopulmonary window – case report and review of the literature. *Prenat Cardio* 2021; 11: 43-50.
35. Rudziński A, Kordon Z. Zespoły heterotaksji u dzieci. W: Skalski J., Religa Z (red.). *Kardiochirurgia dziecięca*. Wydawnictwo Naukowe Śląsk, Katowice 2003; 22.
36. Rudziński A. Comments on a report of the aorto-pulmonary window (APW) type I coexisting with pulmonary valve stenosis and occluded arterial duct, detected prenatally at 26 weeks of gestation. *Prenat Cardio* 2015; 5: 34-35.
37. Everett A, Scott Lim D. *Illustrated Field Guide to Congenital Heart Disease and Repair*. Scientific Software Solutions, Charlottesville VA, USA, 2021.
38. Van Son JAM, Puga FJ, Danielson GK, Seward JB, Mair DD, Schaff HV, et al. Aortopulmonary window: factors associated with early and late success after surgical treatment. *Mayo Clin Proc* 1993; 68: 128-133.

Division of work:

Marcin Wiecheć (ORCID: 0000-0003-0656-6614): research concept and design, collection and/or assembly of data, writing the article.
Agnieszka Nocuń (ORCID: 0000-0002-6934-6304): collection and/or assembly of data, writing the article, critical revision of the article.
Malwina Merta (ORCID: 0009-0002-0060-0578): collection and/or assembly of data.
Katarzyna Januszewska (ORCID: 0000-0001-5031-150X): critical revision of the article.
Edward Malec (ORCID: 0009-0003-3770-7034): final approval of the article.